

## GUIDELINE

# S2k guideline basal cell carcinoma of the skin (update 2023)

**Berenice M. Lang**<sup>1</sup>  | **Panagiotis Balermipas**<sup>2</sup> | **Andrea Bauer**<sup>3</sup> | **Andreas Blum**<sup>4</sup> | **Thomas Dirschka**<sup>5,6</sup> | **Markus Follmann**<sup>7</sup> | **Jorge Frank**<sup>8</sup> | **Bernhard Frerich**<sup>9</sup> | **Klaus Fritz**<sup>10</sup> | **Axel Hauschild**<sup>11</sup> | **Ludwig M. Heindl**<sup>12</sup> | **Hans-Peter Howaldt**<sup>13</sup> | **Stephan Ihrler**<sup>14</sup> | **Vinodh Kakkassery**<sup>15</sup> | **Bernhard Klumpp**<sup>16,17</sup> | **Albrecht Krause-Bergmann**<sup>18</sup> | **Christoph Löser**<sup>19</sup>  | **Markus Meissner**<sup>20</sup> | **Michael M. Sachse**<sup>21</sup> | **Max Schlaak**<sup>22</sup> | **Michael P. Schön**<sup>8</sup> | **Lutz Tischendorf**<sup>23</sup> | **Michael Tronnier**<sup>24</sup> | **Dirk Vordermark**<sup>25</sup> | **Julia Welzel**<sup>26</sup>  | **Michael Weichenthal**<sup>11</sup> | **Susanne Wiegand**<sup>27</sup> | **Roland Kaufmann**<sup>28</sup> | **Stephan Grabbe**<sup>1</sup> 

### Correspondence

Prof. Dr. med. Stephan Grabbe, Department of Dermatology, Mainz University Medical Center, Langenbeckstraße 1, 55131 Mainz, Germany. Email: [stephan.grabbe@unimedizin-mainz.de](mailto:stephan.grabbe@unimedizin-mainz.de)

This guideline was developed under the leadership of the German Cancer Society (DKG), the German Dermatological Society (DDG), and the Dermatologic Cooperative Oncology Group (DeCOG).

Due to the limited wordcount, some parts of this printed version of the guideline have been shortened. The long version is available at: <https://register.awmf.org/de/leitlinien/detail/032-021>

### Summary

Basal cell carcinoma is the most common malignant tumor in the fair-skinned population and its incidence continues to rise. An update of the S2k guideline with the participation of all specialist societies familiar with the clinical picture and previous literature research is of great importance for the quality of care for affected patients. In addition to epidemiology, diagnostics and histology are discussed. After risk stratification, therapy is divided into topical, systemic and radiation therapy. Surgical removal remains the treatment of first choice in most cases. The approval of anti-PD1 inhibitors for locally advanced and metastatic tumors has opened up a new option in second-line therapy (after hedgehog inhibitors).

## PREAMBLE

This chapter is available in the AWMF long version.

## EPIDEMIOLOGY, CLINICAL PRESENTATION, GENETICS

### Statements

Cutaneous basal cell carcinoma is the most common malignant tumor in Central Europe. Clinically, the tumor is characterized by infiltrative and destructive local growth, whereas metastasis is uncommon. In Germany, the incidence is at least 200 new cases per 100,000 population per year.

Basal cell carcinomas arise *de novo*.

Risk factors are UV exposure as well as genetic predisposition (skin type, gender, syndromes).

The same patient may experience multiple primary tumors over the course of years or decades.

(strong consensus)

Basal cell carcinoma (BCC) is the most common malignant tumor in Central Europe.<sup>1</sup> Characterized by destructive local growth, it is an epithelial neoplasm with basaloid differentiation arising from stem cells within the hair follicle and interfollicular epidermis.<sup>2</sup> Clinically, it presents as skin-colored, erythematous, or brownish-red nodules, plaques (for example, in superficial BCC [sBCC]), or ulcers – depending on site and disease stage. Classic nodular BCC (nBCC) presents as a shiny, pearly nodule with prominent margins laced with telangiectasias; there may be central ulceration. The following subtypes can be distinguished based on their different clinical appearance: nodular BCC, superficial BCC, sclerosing BCC, pigmented BCC, ulcerated BCC (ulcus rodens), destructive BCC (ulcus terebrans, historic term). Ulceronodular subtypes account for 60%–80% of all BCC cases.<sup>3</sup>

The incidence of BCC has steadily increased in recent years. In Germany, it is currently reported to be approxi-

This is an open access article under the terms of the [Creative Commons Attribution-NonCommercial](https://creativecommons.org/licenses/by-nc/4.0/) License, which permits use, distribution and reproduction in any medium, provided the original work is properly cited and is not used for commercial purposes.

© 2024 The Author(s). *Journal der Deutschen Dermatologischen Gesellschaft* published by John Wiley & Sons Ltd on behalf of Deutsche Dermatologische Gesellschaft.

mately 200/100,000 population per year.<sup>4–6</sup> This number is likely to be significantly higher, given that most cancer registries only record the first occurrence of BCC and multiple tumors are not represented. The incidence has been predicted to continue to increase in the decades to come.<sup>7</sup> For ethnic groups from Central and Northern Europe, the life-time prevalence has been estimated to more than 10%.<sup>8</sup> Based on data from cancer registries, the mean age of disease onset is currently 73 (men) and 71 (women), respectively, in Germany. While both genders are affected, the disease occurs slightly more often in men.<sup>4</sup> BCCs typically exhibit a locally infiltrative and destructive growth type. Metastasis formation is very rare (estimated incidence 0.0028%–0.55%).<sup>9</sup> Basal cell carcinomas account for more than 80% of all epithelial skin tumors and occur most commonly on head and neck, followed by trunk and extremities.<sup>6,10,11</sup> Basal cell carcinomas can only develop in skin areas with hair follicles; consequently, primary manifestation cannot occur on mucous membranes or palms and soles.

Activation of the sonic hedgehog (SHH) signaling pathway plays a key role in the development of BCCs. A mutation in the inhibitor *patched* (PTCH) of SHH causes uncontrolled activation of *smoothened* (SMO) rendering keratinocytes resistant to apoptosis. Ten percent of sporadic BCCs exhibit an activating mutation in SMO, while 90% are caused by an inactivating mutation in PTCH. The latter is also responsible for BCCs associated with syndromes such as basal cell carcinoma syndrome and xeroderma pigmentosum.<sup>9</sup> In addition, (UV-triggered) point mutations in p53 have been reported to be involved in the development of BCCs.<sup>12</sup> However, a study from 2016 also revealed the large variety of genetic mutations in BCCs. Although 85% of examined BCCs ( $n = 293$ ) showed mutations in the SHH signaling pathway (PTCH1 [73%], SMO [20%], SUFU [8%]) and 61% in TP53, 85% of the BCCs had additional mutations in other cancer-associated genes (MYCN [30%], PPP6C [15%], STK19 [10%], LATS1 [8%], ERBB2 [4%], PIK3CA [2%], NRAS/KRAS/HRAS [2%], PTPN14 [23%], RB1 [8%], FBXW7 [5%]). While the relevance of these mutations needs to be further investigated, they might play a future role in the treatment of locally advanced BCC (laBCC) or metastatic BCC (mBCC).<sup>13</sup>

Intensive UV exposure is regarded as a major risk factor for the development of BCCs. Apart from chronic exposure, intermitting high exposure peaks (sunburns, especially in childhood) are of particular relevance.<sup>14–17</sup> Consequently, the use of tanning beds carries a high risk.<sup>18</sup> Compared to the general population, patients with very high occupational UV exposure have a significantly higher risk of developing BCCs (*odds ratio* [OR] 1.43; 95% confidence interval [CI] 1.23–1.66).<sup>19,20</sup> Overall, however, this correlation is – compared to squamous cell carcinoma – less pronounced and consistent.<sup>20,21</sup> Currently, however, the legal prerequisite for recognition of BCC as an occupational disease due to chronic solar UV exposure (BK5103) is not fulfilled in Germany.<sup>22</sup> Further risk factors include:

male gender, skin type I and II according to Fitzpatrick (individuals with genetically determined low skin pigmentation), BCC in personal history, chronic exposure to arsenic, exposure to ionizing radiation, long-lasting immunosuppression, and genetic syndromes (basal cell carcinoma syndrome, xeroderma pigmentosum). Scars and chronic ulcerations are especially important for development of BCCs in non-chronically UV-exposed areas.

## GENODERMATOSES WITH INCREASED INCIDENCE OF BASAL CELL CARCINOMA

This chapter is available in the AWMF long version.

## DIAGNOSIS

### Clinical Diagnosis

#### Statement

Inspection of the patient without additional tools is suitable for making a suspected clinical diagnosis. (strong consensus)

#### Recommendation

Following the diagnosis of BCC, a total body skin examination shall be performed or recommended. (strong consensus)

BCC is marked by great clinical heterogeneity. Typical features of ulceronodular lesions in particular, consist of a pearly sheen, telangiectasias, raised margins, central ulceration, and a cystic appearance. Superficial BCC is usually characterized by erythematous, frequently multiple macules or plaques with central erosion (and bleeding), whereas sclerosing BCC has a whitish, atrophic appearance. The clinical presentation alone does not allow for definitive conclusions with respect to the histological subtype.<sup>23,24</sup>

Factors that are crucial for assessing the risk of recurrence or aggressive growth include the histological subtype as well as clinical parameters, such as size, location, clinical margins, and aspects of the patient's history (recurrence, history of radiation therapy at the tumor site). Accordingly, this information must be collected and included in the risk assessment.

The presence of a BCC generally increases the risk of developing other epithelial malignancies. While this is true for sun-exposed skin of the head and neck region and the upper extremities in particular, it also applies – albeit to a lesser extent – to skin not exposed to the sun. A total body skin examination is therefore recommended. In the diagnostic workup of BCC, such an examination involves complete inspection of the skin including the scalp.

## Non-invasive diagnostic procedures

### Dermoscopic diagnosis

#### Statement

Dermoscopy may contribute to improving the reliability of the clinical diagnosis of BCC. (strong consensus)

This chapter is available in the AWMF long version.

### Confocal laser microscopy

#### Statement

Confocal laser microscopy may be useful in the diagnosis of BCC. (strong consensus)

This chapter is available in the AWMF long version.

### Optical coherence tomography

#### Statement

Optical coherence tomography may be useful in the diagnosis of BCC. (strong consensus)

#### Statement

Confocal laser microscopy and optical coherence tomography may be useful in assessing the effect of topical therapies for BCC. (strong consensus)

This chapter is available in the AWMF long version.

### High-frequency ultrasound

This chapter is available in the AWMF long version.

### Cross-sectional imaging

Only in certain cases of BCC advanced diagnostic imaging is indicated. This includes laBCC as well as lesions where there is clinical suspicion of perineural growth or metastasis.<sup>25</sup>

### Locally advanced basal cell carcinoma (laBCC)

#### Recommendation

If there is clinical suspicion of osseous infiltration, computed tomography and/or contrast-enhanced magnetic resonance imaging shall be performed to assess the extent of intraosseous tumor spread. (strong consensus)

Locally advanced BCC can infiltrate the skull, dura, and brain through continuous growth. The incidence of intracranial invasion has been reported to be 0.3%.<sup>26,27</sup> If clinical examination shows a fixed tumor mass above a soft area with a palpable osseous rim, infiltration of the skull must be suspected and further imaging studies are indicated. While computed tomography (CT) allows for detailed, high-resolution visualization of bone destruction, especially with respect to cortical bone, it is only of limited value for the detection of intraosseous tumor spread in cancellous bone or bone marrow.<sup>28</sup> Compared to CT, magnetic resonance imaging (MRI) is inferior when it comes to assessing cortical bone; it is, however, clearly superior with respect to visualizing soft tissue and thus the method of choice for assessing both intraosseous and intracranial spread. Here, fat-suppressed T2-weighted and contrast-enhanced T1-weighted sequences allow for differentiation between tumor and fatty bone marrow and thus facilitate detailed visualization of tumor spread in the medullary cavity of the infiltrated bone.<sup>29</sup>

### Periorbital basal cell carcinoma

#### Recommendation

If orbital invasion is clinically suspected, computed tomography of the orbit shall be performed to assess bone destruction, and contrast-enhanced magnetic resonance imaging of the orbit to assess intraorbital tumor spread. (strong consensus)

This chapter is available in the AWMF long version.

### Perineural growth

The data on the frequency of perineural spread in BCC range from 0.18% to 3%.<sup>30–33</sup> Prospective studies suggest that the higher values are more likely to be correct and contribute significantly to subclinical spread and an increased risk of recurrence.<sup>34,35</sup> Perineural spread is also more common in deeply infiltrating BCC. In advanced findings, MRI is the most sensitive imaging technique for diagnosing perineural tumor growth before surgery or radiation.<sup>36</sup> In principle, however, the extent of perineural growth is significantly underestimated, as imaging detection is only possible above a certain tumor mass, whereas small focal or thin-layered tumor growth along smaller nerves cannot usually be detected by imaging.<sup>37</sup> MRI with fat-saturated high-resolution contrast-enhanced T1w sequences is the method of choice if perineural growth is suspected.

## Metastatic basal cell carcinoma

### Recommendation

If metastasis is clinically suspected, cross-sectional imaging studies shall be performed, and the primary histology shall be reevaluated. (strong consensus)

This chapter is available in the AWMF long version.

## Nevoid basal cell carcinoma syndrome

### Recommendation

If nevoid basal cell carcinoma syndrome is suspected, imaging studies to rule out additional malignancies and to detect associated abnormalities should be performed using magnetic resonance imaging in order to prevent radiation-induced neoplasms. (strong consensus)

This chapter is available in the AWMF long version.

## HISTOLOGY

### Recommendation

The diagnosis of BCC shall be confirmed by histological examination of the excised specimen following a biopsy and/or therapeutic excision, depending on the size of the tumor and the therapeutic approach. Exceptions may be made for multiple superficial tumors or in case of basal cell carcinoma syndrome. (strong consensus)

### Statement

Subclinical spread can be assessed with sufficient certainty only histologically; this applies to the sclerosing subtype in particular, which is histologically characterized by fibrosis. (strong consensus)

### Statement

The highest accuracy for histological detection of subclinical spread is achieved by microscopically controlled surgery. (strong consensus)

### Recommendation

During tissue processing, the potential inhomogeneity of tumors should be taken into account. If necessary, serial sections should be examined. (strong consensus)

### Statement

The histopathological diagnosis is performed on routine H&E-stained sections; only in rare, specific situations are special stains or immunohistology useful. (strong consensus)

### Recommendation

Apart from the diagnosis, the dermatopathology report shall include the following information:

- vertical tumor diameter (tumor thickness),
- information about the excision margins.

Moreover, the report should contain – if applicable – information about the histological subtype. This applies, in particular, if there is evidence of infiltrative growth (narrow strands) and/or fibrosing/sclerosing or perineural growth. (strong consensus)

In everyday clinical practice, the diagnostic workup usually includes punch or excisional biopsies both to confirm the diagnosis and to determine the tumor characteristics the subsequent therapeutic approach in each individual case is based upon. In particular, the diagnosis of tumors with a multicentric growth pattern frequently requires examination of serial sections through the entire punch specimen. Moreover, serial sections increase the accuracy with respect to both subclassification and assessment of the depth of invasion.<sup>38</sup> However, given the inhomogeneities in tumor architecture, subtype classification using punch biopsies is frequently not sufficiently reliable.<sup>39</sup> The highest accuracy for histological detection of subclinical spread is achieved by microscopically controlled surgery.<sup>40,41</sup> Similar problems are encountered when measuring the vertical tumor diameter (tumor thickness), which is considered an important parameter in terms of the therapeutic approach chosen (surgical vs. non-surgical). In general, the dermatopathology report shall contain information on the vertical tumor diameter; in analogy to melanoma and squamous cell carcinoma, it is measured from the granular layer down to the deepest tumor margins. If the tumor extends down to the deep margin of the biopsy, the tumor thickness shall be reported as minimal tumor thickness. For shave excisions as well, the tumor thickness should be reported along with the surgical method used. In case of conventional histological processing, information concerning the minimum resection margin should be provided, if possible.

Horizontal tumor spread is measured clinically; it is frequently neither useful nor feasible to do such measurements on fixed tissue. The distance of tumor cells from the lateral and deep margins of the specimen is not measured for partial excisions or biopsies; moreover, such measurement is unnecessary if the excision margins are processed and examined separately, and it is even misleading when dealing with tumors with a multicentric growth pattern. Instead of the histological tumor diameter, the presence of tumor strands (depending on the growth pattern) that extend close to the excision margins as well as their exact location should be specified in the histopathological report. In general, any dermatopathology report referring to the excision of a tumor shall include information about the completeness of its removal based on the surgical method chosen; this requires close communication between surgeon and pathologist.

The “cell of origin” of BCC has not been conclusively characterized. Apart from basal cells of the interfollicular epidermis, primitive hair follicle cells have also been implicated as they share many common morphological and histochemical features.<sup>42</sup> Some authors therefore use the term “trichoblastic carcinoma”. BCC is characterized by great morphological variability, both clinically and histologically. Thus, a given tumor may exhibit various types of differentiation, especially in relation to adnexal structures (e. g. follicular, sebocytic, adenoid/glandular).

In terms of treatment considerations, the growth pattern of a given tumor is of much greater clinical relevance than the cellular differentiation pattern.<sup>43</sup> Tumors characterized by infiltrative growth (narrow strands) and/or fibrosing/sclerosing as well as perineural growth often exhibit subclinical spread and also have a greater tendency for recurrence than well-circumscribed lesions. The dermatopathology report should therefore include information relating to these characteristics. Increased melanin pigmentation and a cystic growth pattern are no relevant prognostic factors. Subtype classification should be based on WHO guidelines.<sup>3</sup> In this context, it is of key importance for subsequent treatment planning to distinguish between nodular, superficial, infiltrative, and sclerosing subtypes. Other subtypes according to the aforementioned classification include micronodular, fibroepithelial (Pinkus tumor), basosquamous or metatypical (there is controversy as to whether this is a distinct entity), keratotic, cystic, infundibulocystic, adenoid, and pigmented subtypes as well as BCC with adnexal differentiation. It is, however, frequently impossible to unequivocally determine the subtype as the criteria classically associated with a given subtype may be present to varying degrees; in many cases, there is also a combination of various morphological criteria.

The histological diagnosis is made on H&E-stained sections; special stains and immunohistology are rarely required. In analogy to squamous cell carcinoma, tumors can be classified using the TNM classification (UICC). However, in everyday clinical practice this is not useful, given that the T classification is too nonspecific, and that lymph node (N) and distant metastases (M) are rarely found. In patients with BCC, it is therefore not required to provide information on the TNM status.

## RISK STRATIFICATION

Given their locally destructive and usually non-metastatic growth pattern, staging of BCCs according to the TNM classification usually plays no clinical role (T classification is too nonspecific, N and M status is negative in more than 99% of cases). Herein, we therefore present a method of risk stratification for assessing the likelihood of recurrence, which is intended to be a useful tool in the subsequent selection of treatment options.

### Statement

Facial lesions – on and around the nose, eyelids and ears in particular – are characterized by higher recurrence rates than those in other sites.  
(*strong consensus*)

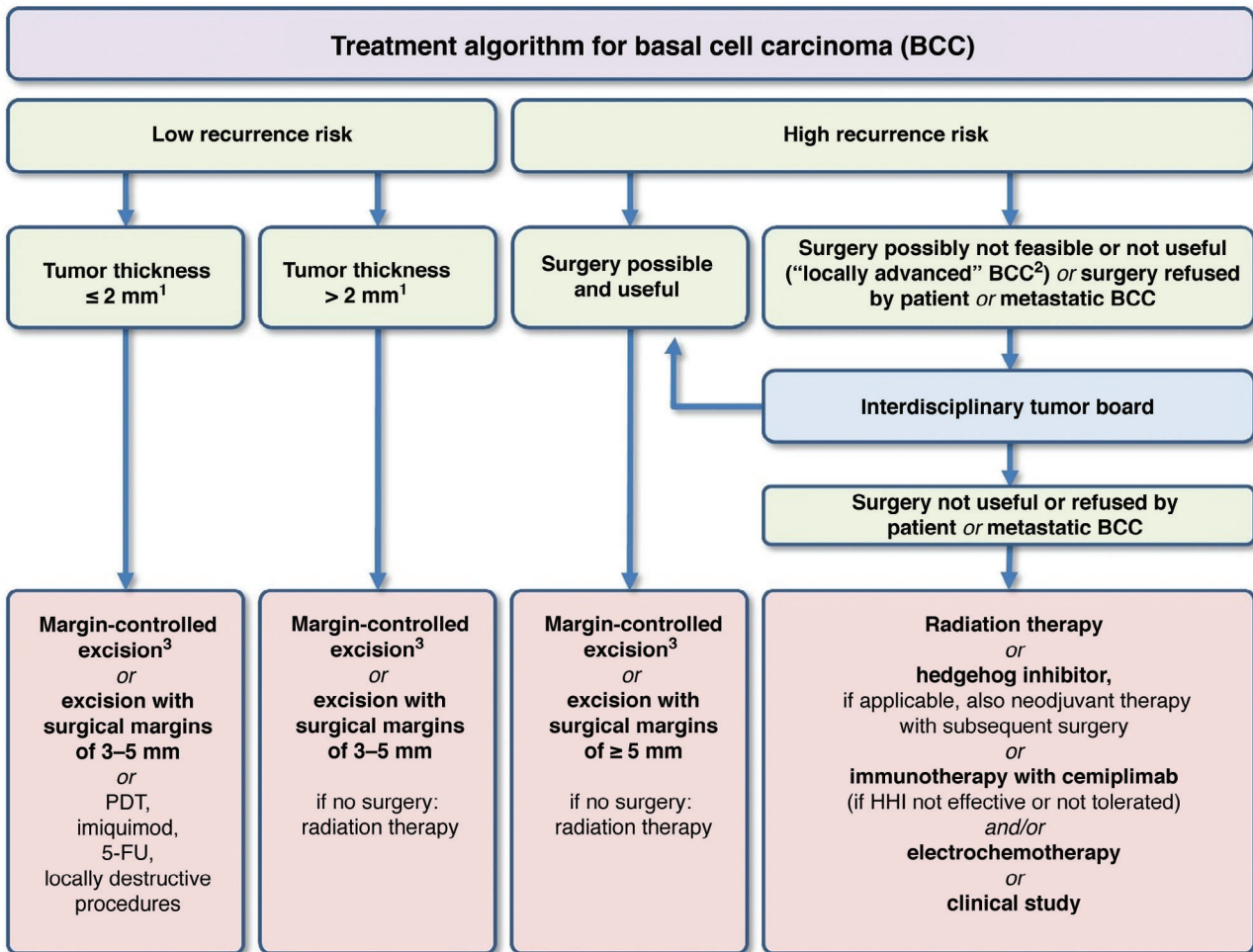
### Recommendation

Risk stratification shall be included in the treatment planning (Figure 1).  
(*strong consensus*)

The following factors are relevant for the **likelihood of recurrence** of BCC:<sup>44</sup>

- **Site:** A number of studies have shown that tumor development in the head/neck region, in particular the central face, is an independent risk factor for recurrence. This has led to the concept of classifying BCCs according to “risk zones”.<sup>45–47</sup> The “H zone” – areas with a high recurrence risk – includes the nose, eyelids/eyebrows/periorbital region, lips, jaw angles, temples and ears/periauricular region as well as genitals, hands, and feet. The “M zone” – areas with a moderate recurrence risk – includes the remaining face and scalp regions (cheek, forehead, scalp) as well as the neck and pretibial region. The trunk and extremities are considered to be “L zones” – areas with a low recurrence risk. The preauricular region as well as the forehead, temples, and nose are marked by an increased incidence of sclerosing BCC.<sup>48</sup>
- **Maximum tumor diameter:** Apart from the tumor site, the recurrence risk of BCC is also determined by the maximum clinical tumor diameter (Table 1).<sup>47,49</sup> The cut-offs given in Table 1 are based on retrospective analyses showing that recurrence in the H zone is more likely for tumors larger than 6 mm and in the M zone for tumors larger than 10 mm.<sup>50</sup> Studies by Breuninger and Dietz have provided clear evidence of a positive correlation between the horizontal tumor diameter and the likelihood of subclinical tumor residuals at a defined distance from the macroscopic tumor margins. If no margin-controlled excision is performed, surgical margins of 3 mm carry a risk for R1 resection of 6% in BCCs with a tumor diameter of < 5 mm. The risk will increase to almost 30% and 45% for tumor diameters of 10 mm and > 20 mm, respectively.<sup>51</sup>
- **Recurrence:** Compared to previously untreated cases of primary BCC, the risk for another local recurrence is increased if there is already a history of prior recurrence.<sup>50,52,53</sup>
- **Tumors arising on chronic radiodermatitis:** Patients who have received radiation therapy with ionizing radiation in the past have a higher risk of developing BCC in the area previously irradiated. In addition, such tumors have an increased risk of recurrence.<sup>54,55</sup>
- **Histological subtype:** See Table 1.
- **Perineural invasion:** BCCs with perineural invasion have been associated with an increased likelihood of recurrence,<sup>56</sup> although this was not confirmed by more recent studies and meta-analyses.<sup>57,58</sup> In previous studies, however, the extent of perineural invasion and the size of the involved nerve have not been quantified histologically, which may explain the variability of this parameter with respect to recurrence risk. Given the unclear data, this parameter is, therefore, still rated a risk factor.

In cases of immunosuppression and in genetic syndromes, there is an increased risk of developing secondary



**Bold font: strong recommendation**, regular font: conditional or open recommendation

<sup>1</sup> There is insufficient evidence for a cutoff regarding tumor thickness. The value given is based on interdisciplinary consensus and should, therefore, be considered as guideline and not a fixed value.

<sup>2</sup> “Locally advanced” basal cell carcinomas comprise a subgroup of tumors that require an interdisciplinary therapeutic concept due to their extent and in particular because of their destructive infiltrative growth.

<sup>3</sup> Whenever feasible, “margin-controlled excision” is generally considered to be first-line therapy.

**FIGURE 1** Therapy algorithm for the treatment of BCC.<sup>49,61–64</sup>

tumors. Immunosuppression will increase the risk of developing BCC by a factor of 4 to 7.<sup>59</sup> In contrast to squamous cell carcinomas, however, basal cell carcinomas exhibit no increased aggressiveness in solid organ transplant recipients.<sup>60</sup>

## SURGICAL TREATMENT

### Recommendation

Complete surgical removal with histological control of excision margins is the most effective treatment for BCC and shall be offered to patients as first-line therapy. (*strong consensus*)

### Recommendation

Depending on the recurrence risk, surgery may be performed either as microscopically controlled surgery or using individualized surgical margins and conventional histology; for superficial variants, horizontal excision (shave excision) with conventional histology may be used. (*strong consensus*)

### Recommendation

If conventional excision is used, surgical margins of 3 to 5 mm should be chosen for BCCs with a low recurrence risk. For BCCs with a high recurrence risk and recurrent tumors, microscopically controlled surgery shall be performed. If possible, this should include complete examination of lateral and deep margins. Otherwise, conventional excision with surgical margins of > 5 mm should be performed. (*strong consensus*)

### Recommendation

First-line therapy for incompletely (R1) excised BCCs is re-excision. For incompletely (R1) excised BCCs with a low recurrence risk, non-surgical procedures may be offered, too. (*strong consensus*)

**TABLE 1** Classification of recurrence risk levels for basal cell carcinoma (adapted from<sup>49</sup>).

	High recurrence risk*	Low recurrence risk
Horizontal tumor diameter and site	- H zone** > 6 mm - M zone** > 10 mm - L zone** > 20 mm	- H zone < 6 mm - M zone < 10 mm - L zone < 20 mm
Borders	Poorly defined	Well-defined
Local recurrence	Yes	No
(Histological) subtype	Sclerosing Infiltrative Metatypical Micronodular	Superficial Nodular Adenoid Trabecular Infundibulocystic Cystic Fibroepithelial (Pinkus tumor)
Tumor on chronic radiodermatitis	Yes	No
Perineural growth	Yes	No

\*Presence of one of these factors results in classification in this category

\*\*H zone: "central" face – eyelids, eyebrows, periorbital region, nose, upper lip, jaw angle, pre- and postauricular region, ears, temples, genitals, hands, feet, M zone: cheeks, forehead, chin, lower lip, scalp, neck, pretibial region, L zone: trunk, extremities

### Statement

The objective of surgical treatment for BCC is the histologically complete removal, including all subclinical residuals (both laterally and towards the base) as well as functionally and aesthetically adequate reconstruction. (*strong consensus*)

More than 95% of all BCCs can be reliably and definitively treated by excision. With a 5-year recurrence rate of 2% to 8%, surgical removal is superior to non-histologically controlled topical procedures (literature review in<sup>65–67</sup>).

Surgical removal is performed either as conventional excision with surgical margins that need to be individually determined based on the recurrence risk (Chapter 5 "Risk stratification") and conventional histological examination or as microscopically controlled surgery (systematic margin control to ensure tumor removal both laterally and towards the base). For superficial and smaller BCCs (especially on the trunk and extremities), shave excision may be considered and is associated with comparable cure rates.<sup>68,69</sup>

Preoperative imaging techniques may help better determine ill-defined tumor margins, especially in case of recurrent lesions (Chapter 3 "Diagnosis").<sup>70</sup>

## Conventional surgery of BCC

Compared to complete, microscopically controlled excision, a higher percentage of R1 situations must be expected when using conventional surgery with surgical margins extending beyond the visible tumor borders followed by histological examination of random cross-sections. Depending on surgical margins and individual tumor-related risk factors (histological subtype), this figure may be as high as 35%.<sup>51,71,72</sup> It should be added, though, that the difference in recurrence rates between the procedures

becomes increasingly small when treating small low-risk BCCs. Gulleth et al. showed in a meta-analysis including 89 publications with 10,261 patients and 16,066 low-risk nodular BCCs with a diameter of < 2 cm that conventional excision with surgical margins of 3 mm was also associated with a very low risk of recurrence.<sup>63</sup> Depending on the tumor-specific risk of local recurrence and/or residual tumor tissue, current guidelines in other countries recommend variable surgical margins of up to 5 mm for low-risk BCCs when using conventional surgery. Regarding high-risk BCCs, lateral margins may reach up to 15 mm, with deep margins extending down to the adipose tissue; for such lesions on the nose, ears, or scalp, deep margins extend down to the underlying fascia, perichondrium, or periosteum.<sup>73,74</sup>

For tumors with a low recurrence risk, surgical margins of 3 to 5 mm should be used to prevent recurrence. Exceptions may be made for small, well-defined nBCCs and pigmented BCC lesions. Here, complete removal is achieved in almost all cases with narrow surgical margins of 2 to 3 mm.<sup>75</sup> If microscopically controlled surgery is not available, tumors with a high recurrence risk (Table 1) should be removed using conventional excision with surgical margins of more than 5 mm. Clinically and histologically determined resection margins may differ due to tissue shrinkage following its removal. Even though such differences are smaller in skin affected by aging and elastotic damage, shrinkage of the excised specimen of approximately 17% to 20% in length and 10% in width can be expected.<sup>76,77</sup> There is currently no data that would justify re-excision in the case of tumor-free margins if the surgical margins determined by histology are not as wide as initially planned clinically.

Conventional surgery has been reported to result in incomplete excisions in 4.7% to 24% of all surgically

removed tumors; however, recurrence must be expected in only 26% to 41% of BCC lesions following incomplete excision. Moreover, approximately one-half of the specimens contain no residual tumor tissue following re-excision.<sup>65,78–80</sup> There are, however, no reliable predictive indicators and recurrent tumors may exhibit a more aggressive growth pattern after incomplete excision.<sup>81,82</sup> Accordingly, re-excision shall be performed after incomplete surgical removal (R1 resection). In the event of high-risk tumors or lesions in critical sites as well as deep recurrences, re-excision should be preferably performed as microscopically controlled surgery to ensure complete tumor clearance.<sup>69,83</sup> Alternatively, radiation therapy may be used for incompletely resected high-risk BCCs, especially if there are factors that complicate a subsequent surgical procedure (extent of the re-excision, comorbidity).

Non-surgical procedures may present an alternative for incompletely resected low-risk BCCs (imiquimod, PDT, cryosurgery, laser, clinical follow-up). If non-surgical procedures (including mere clinical follow-up) are used, close clinical monitoring is required, including optical methods.

## Microscopically controlled surgery of BCC

Microscopically controlled surgery refers to tissue-sparing surgical excision of a tumor with traceable markings and subsequent complete histopathological evaluation of lateral and deep margins. With this method, it is possible to determine the exact location of subclinical tumor spread and, if necessary, to perform targeted re-excision to ensure R0 resection. There are various modifications to this procedure.<sup>41,84</sup> While both frozen sections and paraffin sections may be used for tissue processing, the latter are of greater diagnostic significance (Chapter 4 “Histology”).

The procedure is superior with respect to the frequency of recurrences. In a prospective, randomized study of high-risk facial tumors, the 10-year likelihood of recurrence was lower than for conventional surgery (for primary tumors [n = 408] 4.4% versus 12.2%, p = 0.100; however, the difference was only significant for recurrent tumors [n = 204] 3.9% versus 13.5%, p = 0.023).<sup>85</sup> In particular, microscopically controlled surgery is indicated for tumors associated with an increased likelihood of subclinical spread and recurrence.<sup>41,86</sup> This includes recurrent tumors with extensive subclinical spread<sup>87</sup> and a likelihood of renewed recurrence between 11.6% and 17.4%.<sup>52</sup>

Apart from the higher risk of incomplete excision, conventional surgery with surgical margins may require unnecessarily extensive reconstructive surgery associated with functional and aesthetic impairment.<sup>88</sup>

## Shave excision

### Recommendation

Shave excision may be used to treat small superficial BCCs on the trunk and extremities if there are contraindications for conventional surgery or in case of a larger number of lesions. (*strong consensus*)

This chapter is available in the AWMF long version.

## Surgical treatment of BCC on the eyelids

This chapter is available in the AWMF long version.

## Surgical approach for locally advanced tumors (laBCC)

### Recommendation

For locally advanced tumors, the treatment concept shall be determined by an interdisciplinary tumor board. (*strong consensus*)

For laBCCs not definitively amenable to R0 resection, the feasibility of a surgical procedure shall be reviewed. Not only does this apply to a curative approach but also to palliative indications or to a neoadjuvant approach following the use of hedgehog signaling pathway inhibitors to reduce tumor volume. Prior to surgery, an interdisciplinary tumor board shall determine the appropriate treatment strategy and the requirement for preoperative imaging studies.<sup>74,89</sup>

## RADIATION THERAPY

### Recommendation

For locally advanced BCCs not amenable to complete local resection due to size, site, age, or the patient's comorbidity, the indication for radiation therapy shall be reviewed by an interdisciplinary board. (*strong consensus*)

### Recommendation

Radiation therapy may be offered for the treatment of not locally advanced BCC, if there are contraindications for surgery or if surgery is refused by the patient. (*strong consensus*)

### Recommendation

Radiation therapy should be recommended after surgery, if complete resection is not possible or in cases with infiltration of the perineurium (pn1) of a larger nerve. (*strong consensus*)

### Recommendation

Radiation therapy shall not be used in patients with syndromes and autoimmune disorders that are associated with increased sensitivity to radiation (such as basal cell carcinoma syndrome, xeroderma pigmentosum, lupus erythematosus, scleroderma). (*strong consensus*)

While surgical treatment is the gold standard of local BCC therapy, certain tumor features (size, infiltration of

deep structures, sites associated with mutilating surgery), comorbidity, or patient preference may result in choosing a non-surgical procedure. Multiple publications (case series, retrospective studies, reviews) have shown clinical control rates of 92% to 99% for smaller BCCs and 70% to 90% for high-risk BCCs (large size, high-risk sites, or recurrence) (follow-up period between four months and ten years) for various types of radiation therapy (predominantly brachytherapy, but also electron and orthovoltage radiation therapy).<sup>52,90–98</sup> The only randomized study ( $n = 347$ ) that compared surgery and radiation therapy (1 : 1 randomization) showed surgery to be significantly superior in terms of local disease control, with 99.3% versus 92.5% after 4 years (maximum follow-up period).<sup>99</sup> However, the radiation doses and fractionation schedules used in that study were quite different compared to modern standards and thus somewhat inadequate.

The side effects of radiation therapy are relatively low. As regards the aesthetic outcome, a review of the literature revealed that more than 90% of patients surveyed using a questionnaire rated the aesthetic outcome as “good” or “excellent”.<sup>100</sup> Moreover, there is evidence that the aesthetic outcome depends on the single dose. The following results were achieved with conventionally fractionated or moderately hypofractionated radiation therapy (1.8 to 3 Gy): 19 fractions of 3 Gy each, 94% “excellent” or “good”;<sup>101</sup> hypofractionated regimen with three fractions of 10.2 Gy each, 48% “good”, 50% “acceptable”, 2% “poor”.<sup>102</sup> A meta-analysis of Lee et al. compared the cosmetic outcome of surgical excision (24 studies), Mohs micrographic surgery (13 studies), external-beam radiation therapy (EBRT, 19 studies), and brachytherapy (7 studies) with a total of 21,371 patients with NMSC (no differentiation between BCC and SCC). They concluded that brachytherapy and Mohs micrographic surgery seem to be superior to EBRT and conventional excision in T1-T2 N0 tumors. Local disease control was similar in all four types of therapy.<sup>103,104</sup>

When deliberating the indication for radiation therapy, it is important to consider the patient’s life expectancy in relation to the risk of developing radiation-induced secondary malignancies.<sup>105</sup> Given that the latency period for the development of secondary cutaneous malignancies is at least ten years, this puts the risk for patients above the age of 70 (mean age at the time of BCC diagnosis) into perspective.<sup>106–108</sup>

Although the various types of radiation therapy have not been compared directly, the comparable results obtained in the aforementioned case series suggest that high-energy electrons (4 to 10 MeV), HDR brachytherapy, orthovoltage (100 to 200 kV) or low-voltage irradiation (10 to 50 kV) may be similarly effective. Schulte et al. reported on a total of 1,300 tumors treated with low-voltage (soft) X-rays (94.9% clinical tumor clearance with a mean follow-up period of 77 months).<sup>109</sup> However, extreme caution is required for deeply infiltrating lesions as low-voltage (soft) X-rays

in particular are disadvantageous in terms of tumor control due to their low depth of penetration and efficacy (beyond 5 mm tumor depth, there is < 90% of the physical dose (energy of 50 kV), with exponential decrease towards deeper layers).<sup>90–98</sup> The total dose for normofractionated regimens (five fractions of 2 Gy each per week) should be at least 60 Gy; for larger lesions (> 2 cm horizontal diameter), the dose may be increased to 66 Gy. Very old patients may be offered moderately hypofractionated (five fractions of 2.5 Gy/week up to a total dose of 55 Gy; five fractions of 3 Gy/week up to 54 Gy) or highly hypofractionated regimens (5 to 6 Gy twice per week up to a total dose of 60 Gy).<sup>49,92,104</sup> General recommendations on the dose: in the definitive situation normofractionated (1.8–2 Gy) up to the biologically effective dose (BED)<sub>10</sub> of 70–93.5 Gy and hypofractionated (2.1–5 Gy) up to BED<sub>10</sub> of 56–88 Gy. In general, a somewhat lower dose may be used post-operatively: normofractionated BED<sub>10</sub> 59.5–79.2 Gy and hypofractionated BED<sub>10</sub> 56–70.2 Gy.<sup>110</sup>

There is only limited data comparing radiation therapy with other non-surgical local procedures, such as cryosurgery or imiquimod. In 1986, Hall et al. showed in a prospective, randomized trial that, two years post treatment, the clinical recurrence rate was 4% for radiation therapy compared to 39% for cryosurgery.<sup>111</sup> Furthermore, a small prospective, randomized controlled trial of 27 patients with palpebral BCC showed equal control rates, with better tolerability of irradiation in this region.<sup>112</sup>

Incomplete resection (R1, R2) or perineural growth is associated with high local recurrence rates.<sup>34,113,114</sup> Although there is no prospective randomized data, it appears obvious that postoperative radiation therapy may improve local tumor control in cases with incomplete resection.<sup>37,115,116</sup> Retrospective data from a group of 33 patients with incompletely resected BCC of the medial canthus region showed a local control rate of 100% for patients with positive margins in this high-risk location.<sup>117</sup> A meta-analysis for R0-resected BCCs with perineural growth showed no improvement of the recurrence rate after additional adjuvant radiation therapy compared to surgery alone.<sup>58</sup> In previous studies, however, the extent of perineural invasion and the size of the involved nerve have not been quantified histologically, which may explain the variability of this parameter with respect to recurrence risk. A significant difference in the prognosis depending on the “nerve caliber” has been demonstrated in squamous cell carcinoma, the so-called “extensive pn1”.<sup>118</sup> Generally, postoperative radiation therapy is most likely recommended only in cases with clinical and radiological evidence of macroscopic perineural growth.<sup>110</sup>

Patients unsuitable for radiation therapy include individuals at high risk for the induction of secondary tumors (age < 40, patients with basal cell carcinoma syndrome or other genetic syndromes) as well as patients with connective tis-

sue diseases who are at an increased risk for above-average acute toxicity (lupus erythematosus, scleroderma).

## TOPICAL TREATMENT

### Topical agents

Various topical therapies are used in the treatment of low-risk BCCs and BCCs that occur in special settings, especially in multimorbid elderly patients. The benefits of these agents include, in particular, the possibility of home application, the preservation of surrounding tissue, and a good cosmetic outcome with avoidance of scar formation.<sup>65</sup> In addition, topical agents are important options for patients with multiple (superficial) BCCs.

### Imiquimod

#### Recommendation

Imiquimod 5% cream may be used for the treatment of superficial BCC, primarily if there are contraindications for surgery. (*strong consensus*)

Imiquimod is a toll-like receptor agonist (TLR7 and 8) that can activate both innate and cellular immune responses through induction of proinflammatory cytokines and other mediators. This effect results in targeted killing of tumor cells. Imiquimod 5% cream is applied once daily on five days per week for a total of six weeks. Before going to bed, a thin layer of cream should be applied to the area to be treated and 1 cm of the surrounding skin; the cream should be left on for eight hours. In the EU, imiquimod it is currently approved for the treatment of sBCC with a diameter of less than 2 cm in immunocompetent adults.<sup>119</sup>

Various studies have shown a tumor clearance of 43% to 100% for sBCC.<sup>120</sup> A study of 501 patients comparing surgery and imiquimod showed surgery to be superior, with tumor clearance of 98% after three years compared to 84% in the imiquimod group (relative risk [RR] 0.84, 95% CI 0.78–0.91;  $p < 0.0001$ ). Clinical follow-up after five years showed similar results.<sup>121,122</sup> Another study of 601 patients compared MAL-PDT with imiquimod and 5-fluorouracil (5-FU). After three years, tumor clearance was 80% in the imiquimod group (95% CI 71.6–85.7), 58% in the MAL-PDT group (95% CI 47.8–66.9), and 68% in the 5-FU group (95% CI 58.1–76.3). Approximately 60% of BCCs were located on the trunk.<sup>123</sup>

In summary, the majority of studies show that imiquimod is especially useful for the treatment of sBCC in low-risk locations. Potential adverse effects include an inflammatory reaction in the application area characterized by erythema, swelling, scaling, blistering, and pain. It has been demonstrated that there is a correlation between the severity of this inflammatory reaction and the clinical response.<sup>124</sup>

Imiquimod may also cause flu-like symptoms and localized lymphadenopathy.

### 5-Fluorouracil (5-FU)

#### Recommendation

5-Fluorouracil may be used for the treatment of superficial BCC, primarily if there are contraindications for surgery. (*strong consensus*)

5-Fluorouracil (5-FU) is approved for topical treatment of sBCC, if surgical procedures have been unsuccessful or are not feasible. It is applied twice daily for four weeks at a concentration of 5%. In a recent comparative study between MAL-PDT, imiquimod, and 5-FU, Arits et al. showed 5-FU to be similarly effective in treating sBCC as MAL-PDT but inferior to imiquimod (tumor clearance after twelve months: 72.8% [95% CI 66.8–79.4] for MAL-PDT; 83.4% [78.2–88.9] for imiquimod; 80.1% [74.7–85.9] for 5-FU).<sup>124</sup> The three-year follow-up data of the same study revealed similar results (tumor clearance after 36 months: 58.0% for MAL-PDT [95% CI 47.8–66.9]; 79.7% for imiquimod [95% CI 71.6–85.7]; 68.2% for 5-FU [95%–CI 58.1–76.3]).<sup>123</sup> Adverse effects primarily include an inflammatory reaction in the application area, which may be associated with erythema, swelling, scaling, blistering and even ulceration as well as pain.

Text shortened; the detailed chapter is available in the AWMF long version.

### Diclofenac

#### Recommendation

Given the lack of sufficient data, diclofenac cannot be recommended for the treatment of BCC. (*strong consensus*)

This chapter is available in the AWMF long version.

### Retinostat

#### Recommendation

Given the lack of sufficient data, retinostat cannot be recommended for the topical treatment of BCC at present. (*strong consensus*)

This chapter is available in the AWMF long version.

### Photodynamic therapy (PDT)

#### Recommendation

Photodynamic therapy (with 5-ALA or MAL) may be used for the treatment of thin BCCs, primarily if there are contraindications for surgery. (*strong consensus*)

Photodynamic therapy (PDT) involves the topical application of certain agents (5-aminolevulinic acid [5-ALA] and its ester methyl aminolevulinate [MAL]) that are subsequently converted to a photosensitizer (protoporphyrin IX, PPIX) within the tumor tissue. This is followed by irradiation with red light whose wavelength (570–670 nm) lies within the absorption spectrum of the photosensitizer. Activation of PPIX subsequently results in intracellular generation of singlet oxygen, which causes the destruction of tumor cells. This form of treatment is largely selective for tumor tissue and has to be performed twice per treatment cycle. In Germany, several substances are approved for the treatment of sBCC and nBCC: MAL and a nanoemulsion containing ALA. Prior to treatment, it is recommended to remove scabs and degrease the area to be treated.

Only conventional PDT is approved for the treatment of BCC, that is, PDT using a red lamp (wavelength around 635 nm). There have also been initial studies on the use of daylight-PDT with natural light. In an open, uncontrolled, prospective explorative study of 21 patients and a total of 32 tumors, two sessions within one week resulted in a tumor clearance rate of 74% after one year.<sup>125</sup> In this context, it will be necessary to obtain data from larger studies that also include histological evaluation.

Advantages of PDT include the good or even very good aesthetic outcome and the fact that it can be performed on an outpatient basis. Moreover, treating immunosuppressed patients is also possible.<sup>126,127</sup> The most significant downside is the pain associated with the procedure. Analgesia using local anesthesia (but not topical analgesics) or cold air may be useful. Post-treatment sequelae may include erythema with or without edema as well as erosions and scabs, which resolve after two to six weeks.

Text shortened; the detailed chapter is available in the AWMF long version.

## Cryosurgery

### Recommendation

Cryosurgery may be used for the treatment of small superficial BCCs on the trunk or extremities if there are contraindications for surgery or topical therapies. (*strong consensus*)

This chapter is available in the AWMF long version.

## Laser therapy

### Recommendation

Ablative (CO<sub>2</sub>, erbium:YAG) and non-ablative (dye, Nd:YAG) lasers may be used in the treatment of low-risk BCC if there are contraindications for surgery or topical therapies. (*strong consensus*)

This chapter is available in the AWMF long version.

## SYSTEMIC TREATMENT

### Recommendation

In case of locally advanced or metastatic BCC, treatment with other local (radiation therapy, electrochemotherapy) or systemic (*hedgehog* inhibitors, immunotherapy with anti-PD-1) treatment options shall be discussed by an interdisciplinary tumor board in addition to surgical therapy. Moreover, the possibility of including the patient in a clinical study shall be reviewed. (*strong consensus*)

### Recommendation

In patients with locally advanced or metastatic BCC showing disease progression or intolerance on therapy with a *hedgehog* inhibitor, therapy with anti-PD-1 shall be discussed. Moreover, the possibility of including the patient in a clinical study shall be reviewed. (*strong consensus*)

### Recommendation

For multiple BCCs associated with basal cell carcinoma syndrome, treatment with *hedgehog* inhibitors shall be offered. Moreover, the possibility of including the patient in a clinical study shall be reviewed. (*strong consensus*)

### Recommendation

If remission has been achieved in locally advanced BCC by systemic therapy, surgical eligibility should be re-evaluated. (*strong consensus*)

There have been only very few reports of metastatic basal cell carcinoma (mBCC) with actual histological evidence of metastases. The estimated incidence is between 0.0028% and 0.55%.<sup>9</sup> However, the number of mBCCs may be systematically underestimated, given that patients with BCC usually undergo no metastatic workup. Therefore, potential metastases may not be detected.

In a systematic meta-analysis, all cases of mBCC (n = 172) published from 1970 to 2011 were reviewed in terms of prognosis and treatment. Among the 100 cases that met certain inclusion and exclusion criteria for this meta-analysis, 50% exhibited regional metastases and the other 50% distant metastases. Patients with distant metastases were younger (mean age: 58.0 years) than patients with regional metastases (66.3 years). Although treatment data was available for 93 of the 100 patients, specific outcomes were not reported. Most patients with distant metastases received chemotherapy (36.2%), whereas surgery was the standard treatment most commonly used for regional metastases (87.0%). Median survival of patients with distant metastases was 24 months, compared to 87 months for those with regional metastases. From the individual publications on mBCC it can be seen that – in analogy to metastatic squamous cell carcinoma – predominantly platinum-based chemotherapies were used before 2012. In general, remission rates were between 20% and 30%, and remission was of short duration (2–3 months).<sup>128</sup>

## Hedgehog inhibitors (HHIs)

In 2012, the approval (FDA and EMA) of two HHIs – specific inhibitors of *smoothed*, which plays a key role in BCC development – ushered in a new era of systemic treatment. *Hedgehog* inhibitors had been used in trials of patients with mBCC and laBCC and subsequently been approved (mBCC: vismodegib; laBCC: sonidegib, vismodegib). It should be noted, though, that, prior to the HHI vismodegib and sonidegib trials, there had been no clear criteria for the diagnosis of so-called laBCC. The criteria used in these studies – 1) no indication for conventional surgery or radiation therapy (tumor board decision), 2) multiple lesions and 3) multiple prior treatments – have only been established in recent years. There is, therefore, no published data on other systemic therapies, such as chemotherapy, specifically for the treatment of this particular tumor entity.

Vismodegib is the first newly approved HHI. In the approval study that included 104 patients with laBCC and mBCC, it showed initial remission rates of 48% (laBCC) and 33% (mBCC) as well as a median duration of response of 9.5 and 7.6 months, respectively.<sup>129</sup> An update of the approval study published in 2017 showed remission rates of 48.5% for metastatic and 60.3% for locally advanced tumors 39 months after the end of the recruitment phase.<sup>130</sup> In the latter group, 20 patients experienced complete remission and 18 showed partial remission. Patients with mBCC only saw partial remission; there was no case of complete remission. The median duration of response was 14.8 months (mBCC) and 26.2 months (laBCC). Median overall survival was 33.4 months in the mBCC group and had not yet been reached in the laBCC cohort. There were no treatment-related fatalities. The majority of patients experienced the usual class-specific adverse effects such as muscle spasms, alopecia, fatigue, or weight loss, which resulted in discontinuation of treatment in approximately 30% of the patients. The results were confirmed by another international trial (STEVIE).<sup>131</sup> An update of the STEVIE trial from October 2017 showed remission rates of 68.5% for laBCC and 36.9% for mBCC in 1,215 evaluable BCC patients from 36 nations. The side effect profile was nearly identical to the ERIVANCE study.

Vismodegib was also investigated in a phase 2 study of patients with basal cell carcinoma syndrome.<sup>132</sup> The long-term data now available shows that the 26 patients treated with this HHI (150 mg/day) developed significantly fewer new, surgically eligible BCCs compared to the placebo arm (n = 15).<sup>133</sup> In the majority of patients, vismodegib therapy was interrupted due to adverse events. A subgroup of study participants (n = 18) were given the opportunity to take the HHI for a period of 36 months. Only three of the 18 patients (17%) tolerated vismodegib continuously for the entire time. The majority of the remaining cases discontinued treatment due to adverse events. Unlike the results of the interim analysis, prolonged treatment with vismodegib for 16 to 18 months frequently caused severe and irreversible

alopecia.<sup>132,133</sup> Previous observations that had shown an increased incidence of squamous cell carcinoma were not confirmed in the aforementioned study.<sup>134</sup> Given the spectrum of drug-related adverse events on long-term treatment and the markedly lower drug resistance to HHIs compared to other BCC variants, intermittent therapy with vismodegib seems to be appropriate for this high-risk patient group.<sup>133,135</sup>

Sonidegib, the second HHI approved, received market authorization in Germany in 2017. In the approval study (BOLT), it initially demonstrated a remission rate of 36% and an almost identical spectrum of adverse events as vismodegib at a dose of 200 mg (for which it has now been approved).<sup>136</sup> In the study update one year later, remission rates in the 200 mg group were 57.6% (laBCC) and 7.7% (mBCC). By that time, 18 of the 94 laBCC patients in remission showed progressive disease or had died; more than 50% of the patients had been in remission for more than six months. In the most recent BOLT update from August 2017,<sup>137</sup> remission rates of 56.1% (central review process) and 71.2% (investigator assessment) were reported after a follow-up period of 30 months. The corresponding figures for mBCC were 7.7% and 23.1%. The duration of response was 26.1 months (laBCC) and 24.0 months (mBCC). Median overall survival had not been reached in either population. Two-year survival rates were 93.2% (laBCC) and 69.3% (mBCC). No new, previously unreported adverse events had been observed.

The therapy with HHIs may have many adverse effects and can be distressing for patients. Nevertheless, a significant improvement of the quality of life has been shown on this therapy (based on Skindex-16).<sup>138,139</sup> Given that the considerable therapy-related adverse events limit the average duration of therapy to 6 months, intermittent dosing regimens have been tested in patients with multiple BCCs.<sup>140</sup> One group received four cycles of 150 mg vismodegib for 12 weeks, followed by a therapy-free period of 8 weeks (n = 116). Another group received first 150 mg vismodegib for 24 weeks and then three cycles of 8 weeks free of therapy followed by 8 weeks of therapy (n = 113). With 63% and 54%, respectively, the response rate was in both groups comparable with the long-term treatment. Although tolerability was also not clearly improved compared to long-term treatment, the therapy adherence during the 72-week treatment was > 50%. Based on these data and due to the poor tolerance of long-term treatment (based on clinical experience), an interval therapy consisting of 12 weeks of therapy and a therapy-free interval of 8 weeks has been established as the currently most feasible treatment regimen.

In a recent meta-analysis, response rates and side effect profiles of HHIs from 22 clinical studies with a total of 2,384 patients were evaluated.<sup>141</sup> This revealed that HHIs achieved in general a response rate of 65% and disease control (CR, PR, SD) of 95% in patients with locally advanced or metastatic BCC. All histological subtypes showed a similar therapeutic response.<sup>142,143</sup> Special sites, such as periocular

or perioral BCC, showed also similar response rates.<sup>144–146</sup> While vismodegib showed response rates of 74% (laBCC) and 41% (mBCC), these values were 50% (laBCC) and 14% (mBCC) for sonidegib. However, the analyzed study-based evidence is significantly poorer for sonidegib (2 studies, a total of 237 patients) compared to vismodegib (20 studies, a total of 2,147 patients), and the measurement parameters for assessing the therapeutic response were partly different. In this respect, a comparative assessment of the efficacy of both substances is difficult, given that they have not yet been tested in direct comparison.<sup>147</sup> The side effect profile of both substances seems to be slightly different (more muscle spasms, alopecia, and change in taste on vismodegib, more nausea, loss of appetite, and diarrhea on sonidegib); with an average duration of six months each, however, therapy adherence did not differ between the two substances. In summary, the available study-based evidence does not allow for statements on the superiority of one HHI over another.

In addition, a neoadjuvant therapy with vismodegib has been studied.<sup>148</sup> Here, 55 patients, whose tumors could only be resected with considerable functional or cosmetic impairment, were treated with vismodegib (150 mg daily for 4–10 months) before planned surgery. Subsequently, a less impairing surgery could be chosen in 80% of the patients; 50% of the patients presented histologically with complete remission after HHI treatment, and the majority of cases did not require another surgery. A comparative study obtained similar results.<sup>149</sup>

Initial studies on side effect management indicate a reduction of muscle spasms with concomitant administration of L-carnitine (for example, 500 mg 2 x daily). The use of calcium channel blockers, such as amlodipine, and substances like gabapentin and quinine have also been discussed.<sup>150,151</sup> Due to the absence of significant data, it is not yet possible to give conclusive recommendations on this approach.

## Immune checkpoint inhibitors

Basal cell carcinomas are characterized by a high mutation load, caused by chronic UV exposure as a cofactor of carcinogenesis. Hence, these tumors are good candidates for immunotherapy with checkpoint inhibitors, anti-PD1 antibodies in particular. Following anecdotal reports about their therapeutic benefit in both treatment-naïve as well as treatment-refractory (unsuccessfully treated with HHIs) patients with advanced BCC, studies with various anti-PD1 antibodies had been performed.

A phase 2 approval study with the anti-PD1 antibody cemiplimab, conducted in patients with laBCC and mBCC after unsuccessful therapy with HHIs, showed response rates of 31% and complete remission in 6% of the patients (n = 84 patients, 350 mg cemiplimab every 3 weeks).<sup>152</sup> These outcomes resulted in approval as second-line treat-

ment of cemiplimab in patients with laBCC or mBCC and disease progression or intolerance on HHI therapy.

Smaller studies have also been conducted with nivolumab or pembrolizumab in this indication. Some of these studies have not yet been completed.<sup>153–155</sup> Again, similarly moderate response rates of up to 3% complete remission and 19%–44% partial remission have been reported. Surprisingly, a combination therapy with HHI plus pembrolizumab did not result in a higher remission rate, although HHIs certainly have immunostimulatory effects.<sup>154</sup>

## Electrochemotherapy (ECT)

### Recommendation

In case of locally advanced BCC already treated unsuccessfully with radiation therapy and/or systemic therapy or if there are contraindications for these therapies, electrochemotherapy may be offered. (*strong consensus*)

### Recommendation

In patients with basal cell carcinoma syndrome, electrochemotherapy may be offered. (*strong consensus*)

ECT is a nonthermal method for tumor ablation. Electrical impulses given by special needle electrodes temporarily increase the permeability of cell membranes for chemotherapeutic agents, usually bleomycin (electroporation).<sup>156</sup> The procedure is used for nonspecific treatment of advanced cancers and cutaneous metastases of a wide range of primary cancer types. Several case series have shown that epithelial tumors, such as BCC, may also be treated with this method.<sup>157,158</sup> In a randomized study, complete remission was shown for 87.5% of BCCs treated with electrochemotherapy, with 12% of the lesions requiring a second application of ECT.<sup>159</sup> In this study, ECT showed statistical non-inferiority to surgery. These results have been confirmed in a recently published registry showing a complete remission rate of 81% in 623 BCCs involving 330 patients.<sup>160</sup> Other studies have obtained similar results.<sup>161,162</sup> The cosmetic outcome is rated as excellent by patients.<sup>163</sup> In this respect, ECT has established itself as an additional therapeutic option, especially in patients with laBCC without any other therapeutic option.

ECT is also a good therapeutic option in patients with multiple BCCs, in particular for patients with basal cell carcinoma syndrome.<sup>164</sup>

## TREATMENT OF ELDERLY PATIENTS

This chapter is available in the AWMF long version.

## PREVENTION

This chapter is available in the AWMF long version.

## FOLLOW-UP

### Recommendation

Standardized follow-up of patients with basal cell carcinoma facilitates early detection of local recurrence and secondary tumors. It shall be carried out in a risk-stratified manner:

- *Isolated, surgically treated BCC and low recurrence risk\**: follow-up after 6 months to rule out local recurrence, then once a year.
- *Multiple BCCs, high recurrence risk\*, laBCC, mBCC, syndromes*: follow-up every 3 months. If there is no new BCC or recurrence for more than 2 years, subsequent follow-up once a year. Closer follow-up may be performed in individual cases. (*consensus*)

\*For classification of recurrence risk, see Chapter 5 "Risk stratification"

### Recommendation

Patients shall be instructed to perform regular self-examinations to detect BCC lesions as early as possible. (*strong consensus*)

### Recommendation

Patients with basal cell carcinoma – in particular those with basal cell carcinoma syndrome or chronically immunosuppressed patients – shall protect themselves against excessive sun exposure. (*strong consensus*)

This chapter is available in the AWMF long version.

## AFFILIATIONS

- <sup>1</sup>Department of Dermatology, Mainz University Medical Center, Mainz, Germany
- <sup>2</sup>Department of Radiation Oncology, University Hospital Zürich, Zürich, Switzerland
- <sup>3</sup>Department of Dermatology, University Hospital Carl Gustav Carus, Technical University Dresden, Dresden, Germany
- <sup>4</sup>Dermatology and Teaching Office, Konstanz, Germany
- <sup>5</sup>CentroDerm, Wuppertal, Germany
- <sup>6</sup>Faculty of Health, University of Witten-Herdecke, Witten, Germany
- <sup>7</sup>German Cancer Society, Berlin, Germany
- <sup>8</sup>Department of Dermatology, Venereology and Allergology, Göttingen University Medical Center, Göttingen, Germany
- <sup>9</sup>Department of Oral and Maxillofacial Plastic Surgery, Rostock University Medical Center, Rostock, Germany
- <sup>10</sup>Dermatology and Laser Center, Landau, Germany
- <sup>11</sup>Department of Dermatology, Venereology and Allergology, University Hospital Schleswig-Holstein, Campus Kiel, Germany
- <sup>12</sup>Department of Ophthalmology, Cologne University Medical Center, Cologne, Germany
- <sup>13</sup>Department of Oral and Maxillofacial Plastic Surgery, Gießen University Medical Center, Gießen, Germany
- <sup>14</sup>Laboratory for Dermatohistology and Oral Pathology, Munich, Germany
- <sup>15</sup>Department of Ophthalmology, Chemnitz Medical Center, Chemnitz, Germany
- <sup>16</sup>Department of Diagnostic and Interventional Radiology, Tübingen University Medical Center, Tübingen, Germany
- <sup>17</sup>Department of Radiology, Rems-Murr Medical Center, Winnenden, Germany
- <sup>18</sup>Department of Plastic and Aesthetic Surgery, Gütersloh Medical Center, Germany
- <sup>19</sup>Department of Dermatology, Skin Tumor Center, Ludwigshafen Medical Center, Ludwigshafen, Germany

<sup>20</sup>Dermatology Wiesbaden, Wiesbaden, Germany

<sup>21</sup>Department of Dermatology, Allergology and Phlebology, Bremerhaven Medical Center, Bremerhaven, Germany

<sup>22</sup>Department of Dermatology, Venereology and Allergology, Skin Tumor Center, Charité – Universitätsmedizin Berlin, corporate member of Freie Universität Berlin and Humboldt-Universität zu Berlin, Berlin, Germany

<sup>23</sup>Oral and Maxillofacial Surgery Office, Halle, Germany

<sup>24</sup>Department of Dermatology, Venereology and Allergology, Helios Medical Center, Hildesheim, Germany

<sup>25</sup>Department of Radiation Oncology, Halle University Medical Center, Martin Luther University Halle-Wittenberg, Halle, Germany

<sup>26</sup>Department of Dermatology and Allergology, Augsburg University Medical Center, Augsburg, Germany

<sup>27</sup>Department of Otorhinolaryngology, Leipzig University Medical Center, Leipzig, Germany

<sup>28</sup>Department of Dermatology, Venereology and Allergology, Frankfurt University Medical Center, Frankfurt, Germany

## ACKNOWLEDGEMENTS

Open access funding enabled and organized by Projekt DEAL.

## CONFLICT OF INTEREST INTEREST

Please refer to the AWMF guideline report available online.

## ORCID

Berence M. Lang  <https://orcid.org/0000-0002-4679-3777>

Christoph Löser  <https://orcid.org/0000-0001-7028-3446>

Julia Welzel  <https://orcid.org/0000-0002-6099-7418>

Stephan Grabbe  <https://orcid.org/0000-0002-6863-8719>

## REFERENCES

1. Lomas A, Leonardi-Bee J, Bath-Hextall F. A systematic review of worldwide incidence of nonmelanoma skin cancer. *Br J Dermatol* 2012; 166: 1069-80
2. Peterson SC, Eberl M, Vagnozzi AN, et al. Basal cell carcinoma preferentially arises from stem cells within hair follicle and mechanosensory niches. *Cell Stem Cell* 2015; 16:400-12
3. Kossard S, Epstein EH, Cerio J, et al. Basal cell carcinoma. In: LeBoit PE, Burg G, Weedon D, Sarasin A: *Skin Tumours: Pathology and Genetics. World Health Organization Classification of Tumours*. IARC Press, 2006; 13-20
4. *Krebs in Deutschland für 2013/2014. 11. Ausgabe. Robert Koch-Institut (Hrsg) und die Gesellschaft der epidemiologischen Krebsregister in Deutschland e.V. (Hrsg)*. Berlin, 2017 (DOI: 10.17886/rkipubl-2017-007)
5. Krebsregister RLP Bericht 2017: Nicht-melanozytäre Hauttumore (C44), [https://www.krebsregister-rlp.de/fileadmin/user\\_upload/C44\\_2017.pdf](https://www.krebsregister-rlp.de/fileadmin/user_upload/C44_2017.pdf) "accessed on December 1, 2023"
6. Asgari MM, Moffet HH, Ray GT, Quesenberry CP. Trends in basal cell carcinoma incidence and identification of high-risk subgroups, 1998–2012. *JAMA Dermatol* 2015; 151: 976-98
7. Leiter U, Keim U, Eigentler T, et al. Incidence, Mortality, and Trends of Nonmelanoma Skin Cancer in Germany. *J Invest Dermatol* 2017; 137(9): 1860-1867
8. Chahal HS, Rieger KE, Sarin KY. Incidence ratio of basal cell carcinoma to squamous cell carcinoma equalizes with age. *J Am Acad Dermatol* 2017; 76(2): 353-354
9. Rubin AI, Chen EH, Ratner D. Basal-cell carcinoma. *N Engl J Med* 2005; 353: 2262-2269

10. Lobeck A, Weiss C, Orouji A, et al. Betrachtung des dermatochirurgischen Patientenkollektivs an einem Hauttumorzentrum in Deutschland. *Hautarzt* 2017; 68: 377-384
11. Schäfer I, Reusch M, Siebert J, et al. Health care characteristics of basal cell carcinoma in Germany: the role of insurance status and socio-demographic factors. *J Dtsch Dermatol Ges* 2014; 12(9): 803-11
12. Ling G, Ahmadian A, Persson A, et al. PATCHED and p53 gene alterations in sporadic and hereditary basal cell cancer. *Oncogene* 2001; 20: 7770-8
13. Bonilla X, Parmentieri L, King B, et al. Genomic analysis identifies new drivers and progression pathways in skin basal cell carcinoma. *Nat Genet* 2016; 48(4): 398-406
14. Kricger A, Weber M, Sitas F, et al. Early Life UV and Risk of Basal and Squamous Cell Carcinoma in New South Wales, Australia. *Photochem Photobiol* 2017; 93(6): 1483-1491
15. Kricger A, Armstrong BK, English DR, et al. Does intermittent sun exposure cause basal cell carcinoma? A case-control study in Western Australia. *Int J Cancer* 1995; 60: 489-94
16. Rosso S, Zanetti R, Martinez C, et al. The multicentre south European study 'Helios'. II: Different sun exposure patterns in the aetiology of basal cell and squamous cell carcinomas of the skin. *Br J Cancer* 1996; 73: 1447-54
17. Lashway SG, Worthen ADM, Abuasbeh JN, et al. A meta-analysis of sunburn and basal cell carcinoma risk. *Cancer Epidemiol* 2023; 85:102379
18. Wehner MR, Shive ML, Chren MM, et al. Indoor tanning and non-melanoma skin cancer: systematic review and meta-analysis. *BMJ* 2012; 345:e5909
19. Schmitt J, Haufe E, Trautmann F, et al. Occupational UV-exposure is a Major Risk Factor for Basal Cell Carcinoma: Results of the Population-Based Case-Control Study FB-181. *J Occup Environ Med* 2018; 60(1): 36-43
20. Bauer A, Diepgen TL, Schmitt J. Is occupational UV-irradiation a relevant risk factor for basal cell carcinoma? A systematic review and meta-analysis of the epidemiologic literature. *Br J Dermatol* 2011; 165(3): 612-25
21. Schmitt J, Seidler A, Diepgen TL, Bauer A. Occupational UV-light exposure increases the risk for the development of cutaneous squamous cell carcinoma: a systematic review and meta-analysis. *Br J Dermatol* 2011; 164: 291-307
22. Wissenschaftliche Begründung des Ärztlichen Sachverständigenbeirats „Berufskrankheiten“ beim Bundesministerium für Arbeit und Soziales (2013) Plattenepithelkarzinome oder multiple Keratosen der Haut durch natürliche UV-Strahlung. *GMBI35*: 671-690
23. Christensen E, Mjones P, Grimstad Ø, et al. Diagnostic Accuracy in Subtyping Basal Cell Carcinoma by Clinical Diagnosis Compared with Punch Biopsy. *Acta Derm Venereol* 2016; 96(6): 862-3
24. Roozeboom MH, Kreukels H, Nelemans PJ, et al. Subtyping basal cell carcinoma by clinical diagnosis versus punch biopsy. *Acta Derm Venereol* 2015; 95(8): 996-8
25. Humphreys TR, Shah K, Wysong A, et al. The role of imaging in the management of patients with nonmelanoma skin cancer: When is imaging necessary? *J Am Acad Dermatol* 2017; 76: 591-607
26. Hay A, Strahan JE, Torres A, Kim JY. Basal cell carcinoma with calvarium invasion. *Dermatol Surg* 2011; 37: 399-401
27. Kleydman Y, Manolidis S, Ratner D. Basal cell carcinoma with intracranial invasion. *J Am Acad Dermatol* 2009; 60: 1045-1049
28. Bier G, Hoffmann V, Kloth C, et al. CT imaging of bone and bone marrow infiltration in malignant melanoma – challenges and limitations for clinical staging in comparison to 18FDG-PET/CT. *Eur J Radiol* 2016; 85: 732-738
29. Mitchell DG, Burk DL, Vinitzki S, Rifkin MD. The biophysical basis of tissue contrast in extracranial MR imaging. *Am J Radiol* 1987; 149: 831-837
30. Walling HW, Fosko SW, Geraminejad PA, et al. Aggressive basal cell carcinoma: presentation, pathogenesis, and management. *Cancer Metastasis Rev* 2004; 23(3-4): 389-402
31. Niazi ZB, Lamberty BG. Perineural infiltration in basal cell carcinoma. *Br J Plast Surg* 1993; 46(2): 156-7
32. Mohs FE, Lathrop TG. Modes of spread of cancer of skin. *AMA Arch Derm Syphilol* 1952; 66(4): 427-39
33. Ballanythe AJ, McCarten AB, Ibanez ML. The extension of cancer of the head and neck through peripheral nerves. *Am J Surg* 1963; 106: 651-67
34. Ratner D, Lowe L, Johnson TM, Fader DJ. Perineural spread of basal cell carcinomas treated with Mohs micrographic surgery. *Cancer* 2000; 88(7): 1605-13
35. Martin RC 2nd, Edwards MJ, Cawte TG, et al. Basosquamous carcinoma: analysis of prognostic factors influencing recurrence. *Cancer* 2000; 88(6): 1365-9
36. Galloway TJ, Morris CG, Mancuso AA, et al. Impact of radiographic findings on prognosis for skin carcinoma with clinical perineural invasion. *Cancer* 2005; 103: 1254-125
37. McCord MW, Mendenhall WM, Parsons JT, et al. Skin cancer of the head and neck with clinical perineural invasion. *Int J Radiation Oncology Biol Phys* 2000; 47: 89-93
38. Nguyen KP, Knuiman J, van Erp PEJ, et al. Standard step sectioning of skin biopsy specimen diagnosed as superficial basal cell carcinoma frequently yields deeper and more aggressive subtypes. *J Am Acad Dermatol* 2017; 76: 351-353
39. Genders RE, Kuizinga MC, Teune TM, et al. Does biopsy accurately assess basal cell carcinoma (BCC) subtype? *J Am Acad Dermatol* 2016; 74: 758-7603
40. Böhringer A, Adam P, Schnabl S, et al. Analysis of incomplete excisions of basal-cell carcinomas after breadloaf microscopy compared with 3D-microscopy: a prospective randomized and blinded study. *J Cutan Pathol* 2015; 42: 542-553
41. Löser CR, Rempel R, Möhrle M, et al. S1 guideline: microscopically controlled surgery (MCS). *J Dtsch Dermatol Ges* 2015. 13, 942-51
42. Peterson SC, Eberl M, Vagnozzi AN, et al. Basal cell carcinoma preferentially arises from stem cells within hair follicle and mechanosensory niches. *Cell Stem Cell* 2015; 16: 400-412
43. Armstrong LTD, Magnusson MR, Guppy MPB. Risk factors for recurrence of facial basal cell carcinoma after surgical excision: a follow-up analysis. *J Plast Reconstr Aesthet Surg* 2017; 70(12): 1738-1745
44. Frerich B, Prall F. Basalzellkarzinom der Gesichts und Kopfhaut. Update der Therapieverfahren. *MKG-Chirurg* 2018; 11: 49-63
45. Dubin N, Kopf AW. Multivariate risk score for recurrence of cutaneous basal cell carcinomas. *Arch Dermatol* 1983; 119: 373-377
46. Rigel DS, Robins P, Friedman RJ. Predicting recurrence of basal-cell carcinomas treated by microscopically controlled excision: a recurrence index score. *J Dermatol Surg Oncol* 1981; 7: 807-810
47. Bogelund FS, Philippen PA, Gniadecki R. Factors affecting the recurrence rate of basal cell carcinoma. *Acta Derm Venereol* 2007; 87: 330-334
48. Scrivener Y, Grosshans E, Cribier B. Variations of basal cell carcinomas according to gender, age, location and histopathological subtype. *Br J Dermatol* 2002; 147(1): 41-7
49. NCCN Clinical Practice Guidelines in Oncology: Basal Cell Skin Cancer. *J Natl Compr Canc Netw* 2016; 14: 574-597
50. Silverman MK, Kopf AW, Grin CM, et al. Recurrence rates of treated basal cell carcinomas. Part 1: Overview. *J Dermatol Surg Oncol* 1991; 17(9): 713-8
51. Breuninger H, Dietz K. Prediction of subclinical tumor infiltration in basal cell carcinoma. *J Dermatol Surg Oncol* 1991; 17: 574-8
52. Rowe DE, Carroll RJ, Day CL Jr. Long-term recurrence rates in previously untreated (primary) basal cell carcinoma: implications for patient follow-up. *J Dermatol Surg Oncol* 1989; 15(3): 315-28 und 15: 424-431
53. Tischendorf L. *Kliniksbezogene retrospektive Studie zum Wandel von Prognose und prognostisch relevanten Faktoren operativ behandelter Mund-, Kiefer- und Gesichtstumoren zwischen 1948 und 1982*. Medizinische Dissertation B, Martin-Luther-Universität Halle-Wittenberg, 1991. <https://d-nb.info/1143595866/34> "accessed on December 1, 2023"

54. Karagas MR, McDonald JA, Greenberg ER, et al. Risk of basal cell and squamous cell skin cancers after ionizing radiation therapy. *J Natl Cancer Inst* 1996; 88(24): 1848-53
55. Lichter MD, Karagas MR, Mott LA, et al. Therapeutic ionizing radiation and the incidence of basal cell carcinoma and squamous cell carcinoma. *Arch Dermatol* 2000; 136(8): 1007-11
56. Abushukur Y, Ibrahim Y, Cascardo C, Keeley J, Knackstedt T. Basal Cell Carcinoma With Perineural Invasion: A Systematic Review and Pooled Survival Analysis. *Dermatol Surg*. 2022; 48(11):1159-1165
57. Hill MJ, Hoegler KM, Zhou AE, Snow CR, Khachemoune A. A systematic review of the incidence of basal cell carcinoma with perineural invasion: conventional pathology versus Mohs micrographic surgery. *Arch Dermatol Res*. 2023;315(2):127-132
58. Ash MM, Lacy FA, Patel J, Varma R. Surgery Alone (Without Adjuvant Radiation) Adequately Treats Histologic Perineural Basal Cell Carcinomas: A Systematic Review With Meta-Analysis. *Dermatol Surg*. 2023; 49(1):1-7
59. Penn I. Cancers in renal transplant recipients. *Adv Ren Replace Ther*. 2000; 7: 147-56
60. Lott DG, Manz R, Koch C, Lorenz RR. Aggressive behavior of nonmelanotic skin cancers in solid organ transplant recipients. *Transplantation*. 2010;90(6):683-7
61. Dandurand M, Petit T, Martel P, Guillot B. Management of basal cell carcinoma in adults Clinical practice guidelines. *Eur J Dermatol* 2006; 16(4): 394-401
62. Telfer NR, Colver GB, Morton CA. British Association of Dermatologists. Guidelines for the management of basal cell carcinoma. *Br J Dermatol* 2008; 159(1): 35-48.
63. Gulleth Y, Goldberg N, Silverman RP, Gastman BR. What is the best surgical margin for a Basal cell carcinoma: a meta-analysis of the literature. *Plast Reconstr Surg* 2010; 126(4): 1222-31
64. Reinhold U, Dirschka T, Kurzen H, et al. Praxisnaher Behandlungspfad Basalzellkarzinom. *Der Deutsche Dermatologe* 2016; 10: suppl. 1-12.
65. Trakatelli M, Morton C, Nagore E, et al. Update of the European guidelines for basal cell carcinoma management. *Eur J Dermatol* 2014; 24: 312-29
66. Kauvar AN, Cronin T, Roenigk R, et al. Consensus for nonmelanoma skin cancer treatment: basal cell carcinoma, including a cost analysis of treatment methods. *Dermatol Surg* 2015; 41: 550-71
67. Fukumoto T, Fukumoto R, Oka M, Horita N. Comparing treatments for basal cell carcinoma in terms of long-term treatment-failure: a network meta-analysis. *J Eur Acad Dermatol Venereol*. 2019; 33(11):2050-2057
68. Abramson AK, Krasny MJ, Goldman GD. Tangential shave removal of basal cell carcinoma. *Dermatol Surg* 2013; 3: 387-92
69. Kofler L, Häfner HM, Schulz C, et al. Chirurgische Techniken in der Therapie des Basalzellkarzinoms – eine prospektive Untersuchung. *Hautarzt*. 2020;71(12):960-968
70. Venturini M, Gualdi G, Zanca A, et al. A new approach for presurgical margin assessment by reflectance confocal microscopy of basal cell carcinoma. *Br J Dermatol* 2016; 174: 380-5
71. Kofler L, Breuninger H, Schreiber RH, et al. Three-dimensional histology vs. serial section histology in the treatment of primary basal cell carcinoma: a randomized, prospective, blinded study of 569 tumours. *J Eur Acad Dermatol Venereol*. 2021;35(6):1323-1330
72. Fraga SD, Besaw RJ, Murad F, et al. Complete Margin Assessment Versus Sectional Assessment in Surgically Excised High-Risk Keratinocyte Carcinomas: A Systematic Review and Meta-Analysis. *Dermatol Surg*. 2022;48(7):704-710
73. Nahhas AF, Scarbrough CA, Trotter S. A Review of the Global Guidelines on Surgical Margins for Nonmelanoma Skin Cancers. *J Clin Aesthet Dermatol* 2017; 10: 37-46
74. Newlands C, Currie R, Memon A, et al. Non-melanoma skin cancer: United Kingdom National Multidisciplinary Guidelines. *J Laryngol Otol* 2016; 130: S125-S132
75. Ito T, Inatomi Y, Nagae K, et al. Narrow-margin excision is a safe, reliable treatment for well-defined, primary pigmented basal cell carcinoma: an analysis of 288 lesions in Japan. *J Eur Acad Dermatol Venereol* 2015; 29(9): 1828-31
76. Blasco-Morente G, Garrido-Colmenero C, Pérez-López I, et al. Study of shrinkage of cutaneous surgical specimens. *J Cutan Pathol* 2015; 42: 253-7
77. Kerns MJ, Darst MA, Olsen TG, et al. Shrinkage of cutaneous specimens: formalin or other factors involved? *J Cutan Pathol* 2008; 35: 1093-6
78. Masud D, Moustaki M, Staruch R, Dheansa B. Basal cell carcinomata: Risk factors for incomplete excision and results of re-excision. *J Plast Reconstr Aesthet Surg* 2016; 69: 652-6
79. Bozan A, Gode S, Kaya I, et al. Long-term Follow-up of Positive Surgical Margins in Basal Cell Carcinoma of the Face. *Dermatol Surg* 2015; 41: 761-7
80. Borghi A, Corazza M, Ricci M, et al. Basal cell carcinoma incompletely excised: a case-control study on recurrence. *G Ital Dermatol Venereol* 2016; 151: 145-53
81. Boulinguez S, Grison-Tabone C, Lamant L, et al. Histological evolution of recurrent basal cell carcinoma and therapeutic implications for incompletely excised lesions. *Br J Dermatol* 2004; 151: 623-6
82. Angulo J, Serra-Guillén C, Traves V, et al. Mohs micrographic surgery for repeat excision of basal cell carcinomas on the head with positive margins. *Actas Dermosifiliogr* 2011; 102: 797-804
83. Robinson JK, Fisher SG. Recurrent basal cell carcinoma after incomplete resection. *Arch Dermatol* 2000; 136: 1318-24
84. Lacerda PN, Lange EP, Luna NM, et al. Recurrence rate of basal cell carcinoma among different micrographic surgery techniques: systematic review with meta-analysis. *J Eur Acad Dermatol Venereol*. 2022;36:1178-1190
85. van Loo E, Mosterd K, Krekels GA, et al. Surgical excision versus Mohs' micrographic surgery for basal cell carcinoma of the face: A randomised clinical trial with 10 year follow-up. *Eur J Cancer* 2014; 50(17): 3011-20
86. Sin CW, Barua A, Cook A. Recurrence rates of periocular basal cell carcinoma following Mohs micrographic surgery: a retrospective study. *Int J Dermatol* 2016; 55(9): 1044-7
87. Hoorens I, Batteauw A, Van Maele G, et al. Mohs micrographic surgery for basal cell carcinoma: evaluation of the indication criteria and predictive factors for extensive subclinical spread. *Br J Dermatol* 2016; 174(4): 847-52
88. Wain RA, Tehrani H. Reconstructive outcomes of Mohs surgery compared with conventional excision: A 13-month prospective study. *J Plast Reconstr Aesthet Surg* 2015; 68(7): 946-52
89. Lohuis PJ, Joshi A, Borggreven PA, et al. Aggressive basal cell carcinoma of the head and neck: challenges in surgical management. *Eur Arch Otorhinolaryngol* 2016; 273: 3881-3889
90. Veness MJ, Chong L, Tiver K, GebSKI V. Basal cell carcinoma of the nose: an Australian and New Zealand radiation oncology patterns-of-practice study. *J Med Imaging Radiat Oncol* 2008; 52:382-93
91. Bhatnagar A, Patel R, Werschler WP, et al. High-dose Rate Electronic Brachytherapy: A Nonsurgical Treatment Alternative for Non-melanoma Skin Cancer. *J Clin Aesthet Dermatol* 2016; 9(11): 16-22
92. Valeriani M, Nicosia L, Agolli L, et al. Mono- and Bi-weekly Hypofractionated Radiation Therapy for the Treatment of Epithelial Skin Cancer in Very Elderly Patients. *Anticancer Res* 2017; 37(2): 825-830
93. Piccinno R, Benardon S, Gaiani FM, et al. Dermatologic radiotherapy in the treatment of extensive basal cell carcinomas: a retrospective study. *J Dermatolog Treat* 2017; 28(5): 426-430
94. Delishaj D, Rembielak A, Manfredi B, et al. Non-melanoma skin cancer treated with high-dose-rate brachytherapy: a review of literature. *J Contemp Brachytherapy* 2016; 8(6): 533-540
95. Ballester-Sánchez R, Pons-Llanas O, Candela-Juan C, et al. Electronic brachytherapy for superficial and nodular basal cell carcinoma: a report of two prospective pilot trials using different doses. *J Contemp Brachytherapy* 2016; 8(1): 48-55

96. Duinkerken CW, Lohuis PJ, Heemsbergen WD, et al. Orthovoltage for basal cell carcinoma of the head and neck: Excellent local control and low toxicity profile. *Laryngoscope* 2016; 126(8): 1796-802
97. Pampena R, Palmieri T, Kyrgidis A, et al. Orthovoltage radiotherapy for nonmelanoma skin cancer (NMSC): Comparison between 2 different schedules. *J Am Acad Dermatol* 2016; 74(2): 341-7
98. Rishi A, Hui Huang S, O'Sullivan B, et al. Outcome following radiotherapy for head and neck basal cell carcinoma with 'aggressive' features. *Oral Oncol* 2017; 72: 157-164
99. Avril MF, Auperin A, Margulis A, et al. Basal cell carcinoma of the face: surgery or radiotherapy? Results of a randomized study. *Br J Cancer* 1997; 76(1): 100-6
100. Cho M, Gordon L, Rembielak A, Woo TC. Utility of radiotherapy for treatment of basal cell carcinoma: a review. *Br J Dermatol* 2014; 171(5): 968-73
101. Olschewski T, Bajor K, Lang B, et al. Radiotherapy of basal cell carcinoma of the face and head: Importance of low dose per fraction on long-term outcome. *J Dtsch Dermatol Ges* 2006; 4(2): 124-30
102. Abbatucci JS, Boulter N, Laforge T, Lozier JC. Radiation therapy of skin carcinomas: results of a hypofractionated irradiation schedule in 675 cases followed more than 2 years. *Radiother Oncol* 1989; 14(2): 113-9
103. Lee CT, Lehrer EJ, Aphale A, Lango M, Galloway TJ, Zaorsky NG. Surgical excision, Mohs micrographic surgery, external-beam radiotherapy, or brachytherapy for indolent skin cancer: An international meta-analysis of 58 studies with 21,000 patients. *Cancer*. 2019;125(20):3582-3594
104. Zaorsky NG, Lee CT, Zhang E, Galloway TJ. Skin Cancer Brachytherapy vs External beam radiation therapy (SCRiBE) meta-analysis. *Radiother Oncol*. 2018;126(3):386-393
105. Neville JA, Welch E, Leffell DJ. Management of nonmelanoma skin cancer in 2007. *Nat Clin Pract Oncol* 2007; 4(8): 462-9
106. McKeown SR, Hatfield P, Prestwich RJ, et al. Radiotherapy for benign disease; assessing the risk of radiation-induced cancer following exposure to intermediate dose radiation. *Br J Radiol* 2015; 88(1056): 20150405
107. Preston DL, Shimizu Y, Pierce DA, et al. Studies of mortality of atomic bomb survivors. Report 13: solid cancer and noncancer disease mortality: 1950-1997. 2003. *Radiat Res* 2012; 178(2): AV146-72
108. Wiltink LM, Nout RA, Fiocco M, et al. No Increased Risk of Second Cancer After Radiotherapy in Patients Treated for Rectal or Endometrial Cancer in the Randomized TME, PORTEC-1, and PORTEC-2 Trials. *J Clin Oncol* 2015; 33(15): 1640-6
109. Schulte KW, Lippold A, Auras C, et al. Soft x-ray therapy for cutaneous basal cell and squamous cell carcinomas. *J Am Acad Dermatol* 2005; 53(6): 993-1001
110. Likhacheva A, Awan M, Barker CA, et al. Definitive and Postoperative Radiation Therapy for Basal and Squamous Cell Cancers of the Skin: Executive Summary of an American Society for Radiation Oncology Clinical Practice Guideline. *Pract Radiat Oncol*. 2020;10(1):8-20
111. Hall VL, Leppard BJ, McGill J, et al. Treatment of basal-cell carcinoma: comparison of radiotherapy and cryotherapy. *Clin Radiol* 1986; 37(1): 33-4
112. Garcia-Martin E, Gil-Arribas LM, Idoipe M, et al. Comparison of imiquimod 5% cream versus radiotherapy as treatment for eyelid basal cell carcinoma. *Br J Ophthalmol* 2011; 95(10): 1393-6
113. Leibovitch I, Huilgol SC, Selva D, et al. Basal cell carcinoma treated with Mohs surgery in Australia III. Perineural invasion. *J Am Acad Dermatol* 2005; 53(3): 458-63
114. Brown CI, Perry AE. Incidence of perineural invasion in histologically aggressive types of basal cell carcinoma. *Am J Dermatopathol* 2000; 22(2): 123-5
115. Gupta A, Veness M, De'Ambrosio B, et al. Management of squamous cell and basal cell carcinomas of the head and neck with perineural invasion. *Australas J Dermatol* 2016; 57(1): 3-13
116. Mendenhall WM, Amdur RJ, Hinerman RW, et al. Radiotherapy for cutaneous squamous and basal cell carcinomas of the head and neck. *Laryngoscope* 2009; 119(10): 1994-9
117. Swanson EL, Amdur RJ, Mendenhall WM, et al. Radiotherapy for basal cell carcinoma of the medial canthus region. *Laryngoscope* 2009; 119(12): 2366-8
118. Massey PR, Wang DM, Murad F, et al. Extensive Perineural Invasion vs Nerve Caliber to Assess Cutaneous Squamous Cell Carcinoma Prognosis. *JAMA Dermatol*. 2023;159(12):1332-1338
119. Geisse J, Caro I, Lindholm J, et al. Imiquimod 5% cream for the treatment of superficial basal cell carcinoma: results from two phase III, randomized, vehicle-controlled studies. *J Am Acad Dermatol* 2004; 50(5): 722-33
120. Love E, Bernhard J, Bordeaux J. Topical imiquimod or fluorouracil therapy for basal and squamous cell carcinoma-systematic review. *Arch Derm* 2009; 145(12): 1431-1438
121. Bath-Hextall F, Ozolins M, Armstrong SJ, et al. Surgical excision versus imiquimod 5% cream for nodular and superficial basal-cell carcinoma (SINS): a multicentre, non-inferiority, randomised controlled trial. *Lancet Oncol* 2014; 15: 96-105
122. Williams HC, Bath-Hextall F, Ozolins M, et al. Surgery Versus 5% Imiquimod for Nodular and Superficial Basal Cell Carcinoma: 5-Year Results of the SINS Randomized Controlled Trial. *J Invest Dermatol* 2017; 137: 614e619
123. Roozeboom MH, Arits AH, Mosterd K, et al. Three-Year Follow-Up Results of Photodynamic Therapy vs. Imiquimod vs. Fluorouracil for Treatment of Superficial Basal Cell Carcinoma: A Single-Blind, Noninferiority, Randomized Controlled Trial. *J Invest Dermatol* 2016; 136(8): 1568-74
124. Arits AH, Mosterd K, Essers BA, et al. Photodynamic therapy versus topical imiquimod versus topical fluorouracil for treatment of superficial basal-cell carcinoma: a single blind, non-inferiority, randomised controlled trial. *Lancet Oncol* 2013; 14(7): 647-54
125. Wiegell SR, Skødt V, Wulf HC. Daylight-mediated photodynamic therapy of basal cell carcinomas – an explorative study. *J Eur Acad Dermatol Venereol* 2014; 28(2): 169-75
126. Collier NJ, Ali FR, Lear JT. Efficacy of photodynamic therapy for treatment of basal cell carcinoma in organ transplant recipients. *Lasers Med Sci* 2015; 30(4): 1407-9
127. Alter M, Hillen U, Leiter U, et al. Current diagnosis and treatment of basal cell carcinoma. *J Dtsch Dermatol Ges* 2015; 13(9): 863-74
128. McCusker M, Basset-Sequin N, Dummer R, et al. Metastatic basal cell carcinoma: prognosis dependent on anatomic site and spread of disease. *Eur J Cancer* 2014; 50: 774-78314
129. Sekulic A, Migden MR, Oro AE, et al. Efficacy and safety of vismodegib in advanced basal-cell carcinoma. *N Engl J Med* 2012; 366: 2171-9
130. Sekulic A, Migden MR, Basset-Sequin N, et al. ERIVANCE BCC Investigators. Long-term safety and efficacy of vismodegib in patients with advanced basal cell carcinoma: final update of the pivotal ERIVANCE BCC study. *BMS Cancer* 2017; 17: 332
131. Basset-Séguin N, Hauschild A, Kunstfeld R, et al. Vismodegib in patients with advanced basal cell carcinoma: Primary analysis of STEVIE, an international, open-label trial. *Eur J Cancer* 2017; 86: 334-348
132. Tang JY, Mackay-Wiggan JM, Aszterbaum M, et al. Inhibiting the hedgehog pathway in patients with the basal-cell nevus syndrome. *N Engl J Med* 2012; 366(23): 2180-8
133. Tang JY, Ally MS, Chanana AM, et al. Inhibition of the hedgehog pathway in patients with basal-cell nevus syndrome: final results from the multicentre, randomised, double-blind, placebo-controlled, phase 2 trial. *Lancet Oncol* 2016; 17(12): 1720-1731
134. Mohan SV, Chang J, Li S, et al. Increased Risk of Cutaneous Squamous Cell Carcinoma After Vismodegib Therapy for Basal Cell Carcinoma. *JAMA Dermatol* 2016; 152(5): 527-32
135. Atwood SX, Sarin KY, Whitson RJ, et al. Smoothed variants explain the majority of drug resistance in basal cell carcinoma. *Cancer Cell* 2015; 27(3): 342-53
136. Migden MR, Guminski A, Gutzmer R, et al. Treatment with two different doses of sonidegib in patients with locally advanced or metastatic basal cell carcinoma (BOLT): a multicentre, randomised, double-blind phase 2 trial. *Lancet Oncol* 2015; 16: 716-28

137. Lear JT, Migden MR, Lewis KD, et al. Long-term efficacy and safety of sonidegib in patients with locally advanced and metastatic basal cell carcinoma: 30-month analysis of the randomized phase 2 bolt study. *J Eur Acad Dermatol Venereol* 2018; 32(3): 372-381
138. Hansson J, Bartley K, Karagiannis T, et al. Assessment of quality of life using Skindex-16 in patients with advanced basal cell carcinoma treated with vismodegib in the STEVIE study. *Eur J Dermatol*. 2018;28(6):775-783
139. Schadendorf D, Hauschild A, Fosko S, et al. Quality-of-life analysis with intermittent vismodegib regimens in patients with multiple basal cell carcinomas: patient-reported outcomes from the MIKIE study. *J Eur Acad Dermatol Venereol*. 2020;34(9):e526-e529
140. Dréno B, Kunstfeld R, Hauschild A, et al. Two intermittent vismodegib dosing regimens in patients with multiple basal-cell carcinomas (MIKIE): a randomised, regimen-controlled, double-blind, phase 2 trial. *Lancet Oncol*. 2017;18(3):404-412
141. Nguyen A, Xie P, Litvinov IV, Lefrançois P. Efficacy and Safety of Sonic Hedgehog Inhibitors in Basal Cell Carcinomas: An Updated Systematic Review and Meta-analysis (2009-2022). *Am J Clin Dermatol*. 2023;24(3):359-374
142. Fosko SW, Chu MB, Armbrrecht E, et al. Efficacy, rate of tumor response, and safety of a short course (12-24 weeks) of oral vismodegib in various histologic subtypes (infiltrative, nodular, and superficial) of high-risk or locally advanced basal cell carcinoma, in an open-label, prospective case series clinical trial. *J Am Acad Dermatol*. 2020;82(4):946-954
143. Dummer R, Lear JT, Guminski A, et al. Efficacy of sonidegib in histologic subtypes of advanced basal cell carcinoma: Results from the final analysis of the randomized phase 2 Basal Cell Carcinoma Outcomes With LDE225 Treatment (BOLT) trial at 42 months. *J Am Acad Dermatol*. 2021;84(4):1162-1164
144. Kahana A, Unsworth SP, Andrews CA, et al. Vismodegib for Preservation of Visual Function in Patients with Advanced Periocular Basal Cell Carcinoma: The VISORB Trial. *Oncologist*. 2021;26(7):e1240-e1249
145. Gershoni A, Tiosano A, Ben Ishai M, et al. Vismodegib improves quality of life in patients with periocular locally advanced basal cell carcinoma: subgroup analysis, STEVIE trial. *Eye (Lond)*. 2022;36(2):407-413
146. Ben Ishai M, Tiosano A, Fenig E, Ben Simon G, Yassur I, et al. Outcomes of Vismodegib for Periocular Locally Advanced Basal Cell Carcinoma From an Open-label Trial. *JAMA Ophthalmol*. 2020;138(7):749-755
147. Gutzmer R, Robert C, Loquai C, et al. Assessment of various efficacy outcomes using ERIVANCE-like criteria in patients with locally advanced basal cell carcinoma receiving sonidegib: results from a preplanned sensitivity analysis. *BMC Cancer*. 2021;21(1):1244
148. Bertrand N, Guerreschi P, Basset-Seguín N, et al. Vismodegib in neoadjuvant treatment of locally advanced basal cell carcinoma: First results of a multicenter, open-label, phase 2 trial (VISMONEO study): Neoadjuvant Vismodegib in Locally Advanced Basal Cell Carcinoma. *EclinicalMedicine*. 2021;35:100844
149. Soon SL, Ibrahim SF, Arron ST. A randomized phase II study evaluating vismodegib as neoadjuvant treatment of basal cell carcinoma preceding Mohs micrographic surgery: results and lessons learned. *Br J Dermatol*. 2019;181(1):208-209
150. Lacouture ME, Dréno B, Ascierto PA, et al. Characterization and management of Hedgehog pathway inhibitor-related adverse events in patients with advanced basal cell carcinoma. *Oncologist*. 2016;21(10):1218-1229
151. Bossi P, Ascierto PA, Basset-Seguín N, et al. Long-term strategies for management of advanced basal cell carcinoma with hedgehog inhibitors. *Crit Rev Oncol Hematol*. 2023;189:104066
152. Stratigos AJ, Sekulic A, Peris K, et al. Cemiplimab in locally advanced basal cell carcinoma after hedgehog inhibitor therapy: an open-label, multi-centre, single-arm, phase 2 trial. *Lancet Oncol*. 2021;22(6):848-857
153. Véron M, Chevret S, Grob JJ, et al. Safety and efficacy of nivolumab, an anti-PD1 immunotherapy, in patients with advanced basal cell carcinoma, after failure or intolerance to sonic Hedgehog inhibitors: UNICANCER AcSé NIVOLUMAB trial. *Eur J Cancer*. 2022;177: 103-111
154. Chang ALS, Tran DC, Cannon JGD, et al. Pembrolizumab for advanced basal cell carcinoma: An investigator-initiated, proof-of-concept study. *J Am Acad Dermatol*. 2019;80(2): 564-566
155. Ishii M, Hirai I, Tanese K, et al. Anti-PD-1 antibody therapy for epithelial skin malignancies: An investigator-initiated, open-label, single-arm, multicenter, phase II clinical trial (NMSC-PD1 Study). *Medicine (Baltimore)*. 2020;99(44):e22913
156. Reinhold U. Electrochemotherapy for primary skin cancer and skin metastasis re-lated to other malignancies. *Anticancer Drugs*. 2011; 22(8): 711-8
157. Kreuter A, van Eijk T, Lehmann P, et al. Electrochemotherapy in advanced skin tumors and cutaneous metastases - a retrospective multicenter analysis. *J Dtsch Dermatol Ges* 2015; 13(4): 308-15
158. Jamsek C, Sersa G, Bosnjak M, Groselj A. Long term response of electrochemotherapy with reduced dose of bleomycin in elderly patients with head and neck non-melanoma skin cancer. *Radiol Oncol*. 2020;54(1):79-85
159. Clover AJP, Salwa SP, Bourke MG, et al. Electrochemotherapy for the treatment of primary basal cell carcinoma; A randomised control trial comparing electrochemotherapy and surgery with five year follow up. *Eur J Surg Oncol*. 2020;46(5):847-854
160. Bertino G, Muir T, Odili J, et al. Treatment of Basal Cell Carcinoma with Electrochemotherapy: Insights from the InspECT Registry (2008-2019). *Curr Oncol*. 2022;29(8):5324-5337
161. Hendel K, Jemec GBE, Haedersdal M, Wiegell SR. Electrochemotherapy with bleomycin for basal cell carcinomas: a systematic review. *J Eur Acad Dermatol Venereol*. 2021;35(11):2208-2215
162. Clover AJP, de Terlizzi F, Bertino G, et al. Electrochemotherapy in the treatment of cutaneous malignancy: Outcomes and subgroup analysis from the cumulative results from the pan-European International Network for Sharing Practice in Electrochemotherapy database for 2482 lesions in 987 patients (2008-2019). *Eur J Cancer*. 2020;138:30-40
163. Lyons P, Kennedy A, Clover AJP. Electrochemotherapy and basal cell carcinomas: First-time appraisal of the efficacy of electrochemotherapy on survivorship using FACE-Q. *JPRAS Open*. 2020 25;27: 119-128
164. Kis E, Baltás E, Kinyó A, et al. Successful treatment of multiple basalomas with bleomycin-based electrochemotherapy: a case series of three patients with Gorlin-Goltz syndrome. *Acta Derm Venereol* 2012; 92(6): 648-51

**How to cite this article:** Lang BM, Balermipas P, Bauer A, et al. S2k guideline basal cell carcinoma of the skin (update 2023). *JDDG: Journal der Deutschen Dermatologischen Gesellschaft*. 2024;22:1697–1714. <https://doi.org/10.1111/ddg.15566>